

Case Report

Thyroid-Associated Ophthalmopathy after Radioactive Iodine Therapy for Metastatic Follicular Thyroid Carcinoma

Daisuke Murayama ¹, Soji Toda ¹, Yoichiro Okubo ², Hiroyuki Hayashi,³ Ai Matsui,¹ Mio Yasukawa,¹ and Hiroyuki Iwasaki ¹

¹Department of Breast and Endocrine Surgery, Kanagawa Cancer Center, 2-3-2 Nakao Asahi-ku, Yokohama, Kanagawa 241-8515, Japan

²Department of Pathology, Kanagawa Cancer Center, 2-3-2 Nakao Asahi-ku, Yokohama, Kanagawa 241-8515, Japan

³Department of Pathology, Yokohama Municipal Citizen's Hospital, 1-1 Mitsuzawanishicho Kanagawa-ku, Yokohama, Kanagawa 221-0855, Japan

Correspondence should be addressed to Daisuke Murayama; murayama.dr@gmail.com

Received 26 April 2021; Revised 17 May 2021; Accepted 29 May 2021; Published 11 June 2021

Academic Editor: Désirée Deandreis

Copyright © 2021 Daisuke Murayama et al. This is an open access article distributed under the Creative Commons Attribution License, which permits unrestricted use, distribution, and reproduction in any medium, provided the original work is properly cited.

Thyroid-associated ophthalmopathy (TAO) is an inflammation of the extraocular muscles and periorbital connective tissue caused by autoantibodies against common antigens to both the thyroid and orbit. The release of antigens and induction of hypothyroidism caused by radioactive iodine (RAI) therapy may exacerbate TAO. Here, we present the case of a 67-year-old-woman treated with RAI therapy for metastatic follicular thyroid carcinoma who presented with TAO during the course of sorafenib administration. Tg and TgAb levels were gradually decreased with sorafenib and lenvatinib treatment, and TAO was improved without any ophthalmologic treatment.

1. Introduction

Thyroid-associated ophthalmopathy (TAO) is an inflammation of the extraocular muscles and periorbital connective tissue caused by autoantibodies against common antigens to both the thyroid and orbit such as thyroid-stimulating hormone receptor (TSH-R) [1]. Several reports suggest that the release of antigens and induction of hypothyroidism caused by radioactive iodine (RAI) therapy may exacerbate TAO [2]. Sorafenib is an orally administered inhibitor of vascular endothelial growth factor receptor- (VEGFR-) 1, 2, and 3, RET, RAF, and platelet-derived growth factor receptor (PDGFR)- β [3]. Lenvatinib is also an orally administered inhibitor of VEGFR-1, -2, and -3, fibroblast growth factor receptor-1 to -4, PDGFR- α , RET, and KIT [4]. TAO after RAI for thyroid carcinoma after total thyroidectomy has been reported in a few studies [5–7]; however, the improvement in TAO during the course of sorafenib and lenvatinib treatment for metastases of RAI-refractory

differentiated thyroid carcinoma after total thyroidectomy has not been reported.

2. Case Presentation

A 67-year-old-woman who presented with back pain was referred to our institution to evaluate the cause. Computed tomography (CT) revealed a thyroid tumor and multiple vertebral bone metastases (C5, L4, S1, and left acetabular cartilage) (Figure 1). Biopsy of L4 was performed, and pathological findings showed metastasis of follicular thyroid carcinoma. Denosumab was initiated to address multiple bone metastases, and the patient underwent total thyroidectomy and central neck dissection. Pathological diagnosis was poorly differentiated carcinoma derived from follicular thyroid carcinoma with minimal invasion (Figure 2). After the surgery, the patient received TSH-suppressive therapy with levothyroxine sodium hydrate 100 μ g daily and treated with RAI therapy (3.7 GBq). However, no uptake was

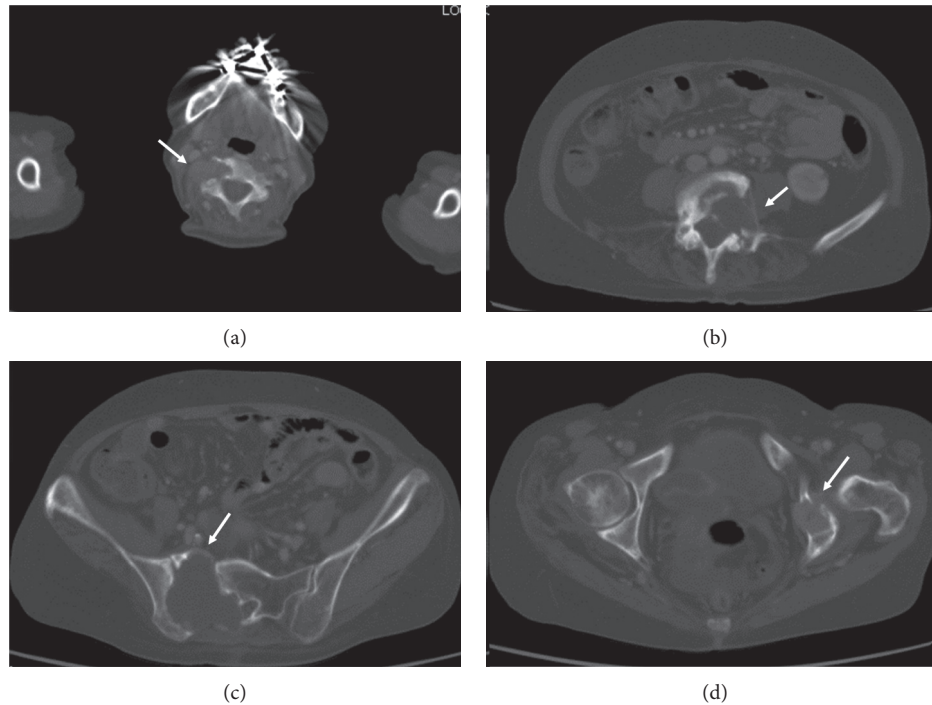


FIGURE 1: Computed tomography revealing bone metastasis (arrow). (a) C5, (b) L4, (c) S1, and (d) left acetabular cartilage.

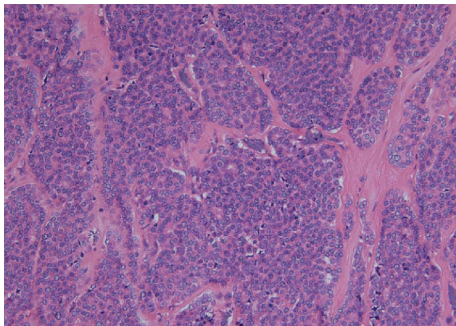


FIGURE 2: Pathological diagnosis of poorly differentiated carcinoma derived from follicular thyroid carcinoma with minimal invasion; Victoria Blue hematoxylin and eosin staining, 200x.

observed in the metastatic lesions (Figure 3). Three months after RAI therapy, external beam radiation therapy (36 Gy/12F) was performed to the lumbar spine and sacrum. Six months after RAI, sorafenib 800 mg was initiated with gradually decreasing dosage because of diarrhea. One year after RAI, the patient presented with diplopia, and magnetic resonance imaging revealed a thickening of the right inferior rectus muscle (Figure 4). Laboratory data obtained the following findings: thyrotropin receptor antibody (TRAb) 11.8 IU/L, euthyroid, thyroglobulin (Tg) 37700 ng/mL, and thyroglobulin antibody (TgAb) 215 IU/L (the normal value of TRAb, Tg, and TgAb are 2.0 IU/L or less, 33.7 ng/mL or less, and 28.0 IU/mL or less, respectively). Lumbar puncture and cytology found no abnormalities, and the patient was diagnosed with TAO. Despite the recommendation of an ophthalmologist, she refused treatment for TAO. However,

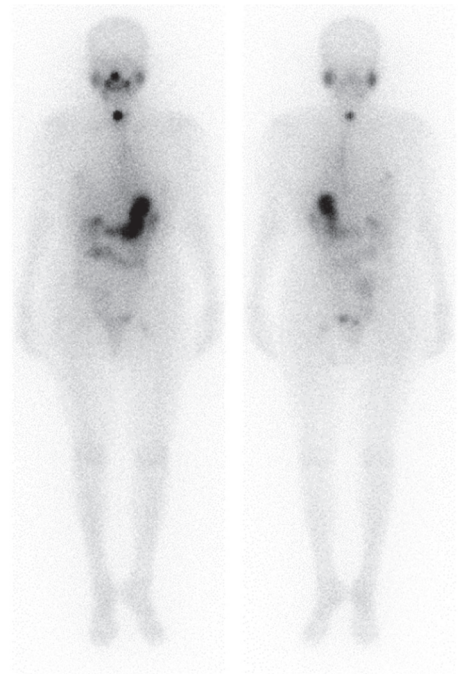


FIGURE 3: Iodine-131 scintigraphy after radioactive iodine therapy. No uptake was observed in the metastatic lesions.

Tg and TgAb gradually decreased with sorafenib and lenvatinib administration, and TAO was improved two years after occurrence (Figure 5). At the time of TAO improvement, Tg and TgAb levels were 1620 ng/mL and 13 IU/L, respectively. During the course of treatment, no changes in bone metastasis were observed on CT.

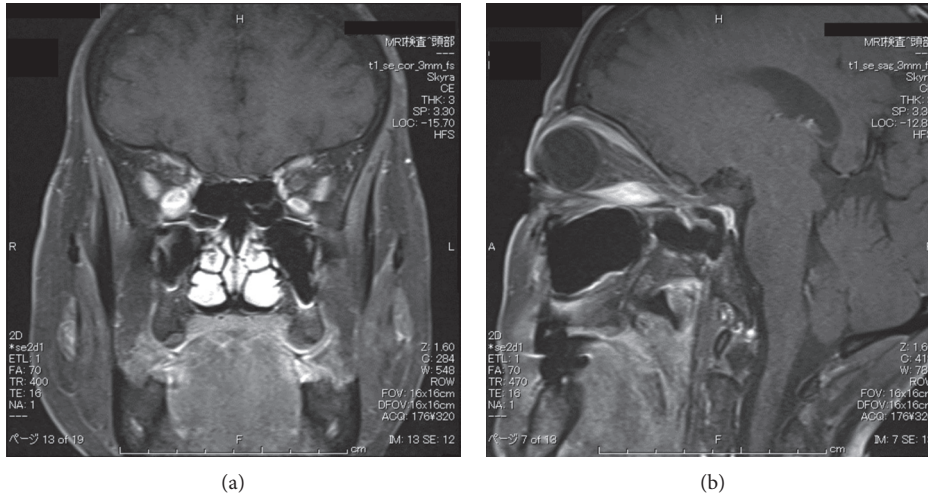


FIGURE 4: Magnetic resonance imaging revealing thickening of the right inferior rectus muscle (asterisk).

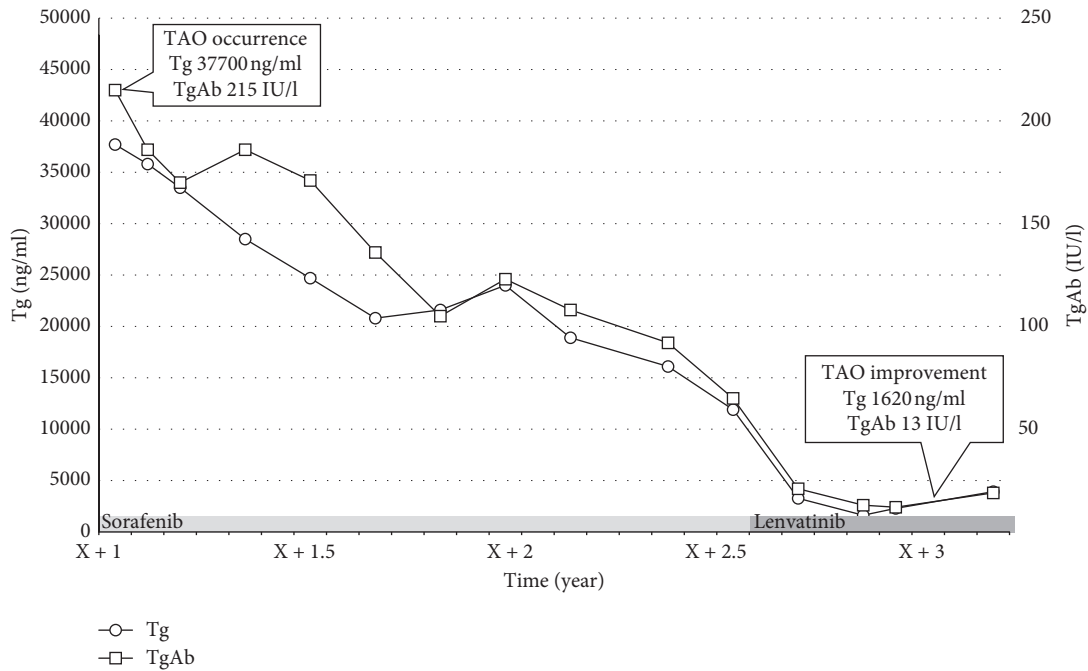


FIGURE 5: Change of thyroglobulin (Tg) and thyroglobulin antibody (TgAb) levels (from thyroid-associated ophthalmopathy occurrence to improvement).

3. Discussion

In 1967, Kriss et al. [8] initially reported the exacerbation of TAO after RAI therapy. Radiation injury appears to induce thyroid antigen leakage, leading to an increased production of TSH-R antibodies [9], which may cause orbital injury, since TSH-R is expressed in orbital tissue [10]. TAO may develop at any time 1–24 months after RAI for Grave’s disease [11]. However, Bartalena and Tanda [12] reported that TAO may occur in patients with no thyroid dysfunction.

Only three case reports of TAO after RAI for thyroid carcinoma have been reported [5–7], and all were treated

with an ablative dose (2.2 to 3.7 GBq). Despite the absence of thyroid tissue after total thyroidectomy for nonmetastatic thyroid carcinoma, TAO occurred after RAI [6, 7]. The time period from RAI to TAO onset is 3–34 years [5–7]. All three previous cases demonstrated no thyroid dysfunction, as with our case.

Lahooti et al. [13] reported a significant positive correlation between serum Tg levels and the presence and severity of ophthalmopathy in patients with Graves’ disease. As for our case, the decline of thyroid antigen (Tg and TgAb) with sorafenib and lenvatinib administration resulted in TAO improvement (Figure 5). However, TRAb was

evaluated only once at TAO onset, and we could not establish whether TRAb was improved with sorafenib and lenvatinib treatment.

In conclusion, our case presented with TAO after RAI. Tg and TgAb levels were gradually decreased with sorafenib and lenvatinib treatment, and TAO was improved without any ophthalmologic treatment.

Data Availability

The datasets used during the current study are available from the corresponding author upon request.

Consent

Written informed consent was obtained from the patients for their anonymized information to be published in this article.

Conflicts of Interest

The authors declare that they have no conflicts of interest.

Acknowledgments

The authors would like to thank Enago (<http://www.enago.com>) for the English language review.

References

- [1] I. M. M. J. Wakelkamp, O. Bakker, L. Baldeschi, W. M. Wiersinga, and M. F. Prummel, "TSH-R expression and cytokine profile in orbital tissue of active vs. inactive Graves' ophthalmopathy patients," *Clinical Endocrinology*, vol. 58, no. 3, pp. 280–287, 2003.
- [2] F. Träisk, L. Tallstedt, M. Abraham-Nordling et al., "Thyroid-associated ophthalmopathy after treatment for Graves' hyperthyroidism with antithyroid drugs or iodine-131," *The Journal of Clinical Endocrinology and Metabolism*, vol. 94, no. 10, pp. 3700–3707, 2009.
- [3] M. S. Brose, C. M. Nutting, S. I. Sherman et al., "Rationale and design of decision: a double-blind, randomized, placebo-controlled phase III trial evaluating the efficacy and safety of sorafenib in patients with locally advanced or metastatic radioactive iodine (RAI)-refractory, differentiated thyroid cancer," *BMC Cancer*, vol. 11, no. 1, p. 349, 2011.
- [4] M. Schlumberger, M. Tahara, L. J. Wirth et al., "Lenvatinib versus placebo in radioiodine-refractory thyroid cancer," *New England Journal of Medicine*, vol. 372, no. 7, pp. 621–630, 2015.
- [5] P. B. Rogers, N. Gupta, G. E. Rose, and P. N. Plowman, "Thyroid eye disease associated with athyria," *British Journal of Ophthalmology*, vol. 84, no. 4, p. 439, 2000.
- [6] A. Antonelli, P. Fallahi, S. Tolari, S. M. Ferrari, and E. Ferrannini, "Thyroid-associated ophthalmopathy and TSH receptor autoantibodies in nonmetastatic thyroid cancer after total thyroidectomy," *The American Journal of the Medical Sciences*, vol. 336, no. 3, pp. 288–290, 2008.
- [7] L. Giovansili, G. Cayrolle, G. Belange, G. Clavel, and M.-L. Herdan, "Graves' ophthalmopathy after total thyroidectomy for papillary carcinoma," *Annales d'Endocrinologie*, vol. 72, no. 1, pp. 42–44, 2011.
- [8] J. P. Kriss, V. Pleshakov, A. L. Rosenblum, M. Holderness, G. Sharp, and R. Utiger, "Studies on the pathogenesis of the ophthalmopathy of Graves' Disease¹," *The Journal of Clinical Endocrinology & Metabolism*, vol. 27, no. 4, pp. 582–593, 1967.
- [9] K. A. Ponto, S. Zang, and G. J. Kahaly, "The tale of radioiodine and Graves' orbitopathy," *Thyroid*, vol. 20, no. 7, pp. 785–793, 2010.
- [10] A. Feliciello, I. Ciullo, G. F. Fenzi, G. Bonavolontà, A. Porcellini, and E. V. Avvedimento, "Expression of thyrotropin-receptor mRNA in healthy and Graves' disease retro-orbital tissue," *The Lancet*, vol. 342, no. 8867, pp. 337–338, 1993.
- [11] S. H. Acharya, A. Avenell, S. Philip, J. Burr, J. S. Bevan, and P. Abraham, "Radioiodine therapy (RAI) for Graves' disease (GD) and the effect on ophthalmopathy: a systematic review," *Clinical Endocrinology*, vol. 69, no. 6, pp. 943–950, 2008.
- [12] L. Bartalena and M. L. Tanda, "Graves' ophthalmopathy," *New England Journal of Medicine*, vol. 360, no. 10, pp. 994–1001, 2009.
- [13] H. Lahooti, T. Shanmuganathan, B. Champion, and J. R. Wall, "Serum thyroglobulin levels in patients with thyroid autoimmunity with and without ophthalmopathy or isolated upper eyelid retraction," *Trends in Immunology*, vol. 3, pp. 22–27, 2015.