

Case Report

Protracted COVID-19 during Treatment of Facial Palsy

Mehrdad Hasibi ¹, Maral Seyed Ahadi ², Hamed Abdollahi ³, and Mehrdad Jafari ⁴

¹Professor of Infectious Diseases, Amiralam Hospital, Tehran University of Medical Sciences, South Saadi St., Tehran, Iran

²Assistant Professor of Neurology, Amiralam Hospital, Iranian Center of Neurological Research, Neuroscience Institute, Tehran University of Medical Sciences, South Saadi St., Tehran, Iran

³Assistant Professor, Department of Anesthesiology, Amiralam Hospital, Tehran University of Medical Sciences, South Saadi St., Tehran, Iran

⁴Assistant Professor, Department of Otolaryngology—Head and Neck Surgery, Imam Khomeini Hospital Complex, Tehran University of Medical Sciences, Valiasr hospital, Baqerkhan St., Tehran, Iran

Correspondence should be addressed to Mehrdad Jafari; mehrdadj82@yahoo.com

Received 8 January 2021; Revised 22 April 2021; Accepted 29 May 2021; Published 8 June 2021

Academic Editor: Peter Berlit

Copyright © 2021 Mehrdad Hasibi et al. This is an open access article distributed under the Creative Commons Attribution License, which permits unrestricted use, distribution, and reproduction in any medium, provided the original work is properly cited.

Neurologic manifestations are increasingly reported as the coronavirus disease 2019 (COVID-19) pandemic continues. This is a report of a COVID-19 patient with Bell's palsy. Case Summary. A 52-year-old man with fever and malaise was tested positive for COVID-19. After a week, he developed right-sided peripheral facial palsy and was treated with corticosteroids in conjunction with antiviral treatment which resulted in complete recovery. Discussion. Concomitant treatment of corticosteroids and antiviral treatment can decrease morbidity in patients with COVID-19-related Bell's palsy.

1. Introduction

The COVID-19 pandemic has been a major health issue affecting millions of people around the world. Although respiratory symptoms are the main clinical features, associated neurologic manifestations are increasingly recognized. Studies have been published describing diverse neurological manifestations from anosmia to life-threatening acute necrotizing encephalopathy. Peripheral facial palsy is one of the neurologic manifestations reported with COVID-19. There is not a consensus regarding facial palsy treatment during the COVID-19 era. This is a report of the successful treatment of a patient with COVID-19-associated facial palsy.

2. Case Report

On July 10, 2020, a 52-year-old man presented to our outpatient clinic in Amiralam Hospital, Tehran, with fever, malaise, and anorexia from 2 days before without any respiratory symptoms. His blood oxygen (O₂) saturation was

95% while breathing room air. Other physical examinations were unremarkable. He was diagnosed with COVID-19 based on a positive RT-PCR test result of the nasopharyngeal sample. The patient did not have any risk factors except class 1 obesity; therefore, he was managed in an outpatient setting with capsule Arbidol 200 mg (an antiviral agent) TID and naproxen 250 mg BID for 7 days. Three days later, his fever subsided and other symptoms partially resolved; however, he complained from new-onset mild dry coughs. One week following symptom onset, the patient developed right-sided facial palsy. On physical examinations, he had a grade V House–Brackmann [1] lower motor neuron facial palsy without any other cranial nerve involvement, parotid swelling, or auditory canal lesions. Other neurologic examinations were unremarkable. The result of brain MRI without contrast was normal. He was initially put on 60 mg prednisolone (to be tapered from the sixth day of treatment) and favipiravir tablet 600 mg three times a day. After 5 days of treatment, the facial palsy recovered partially but he complained of increased dry cough and severe malaise. He underwent a spiral chest CT scan which showed multiple

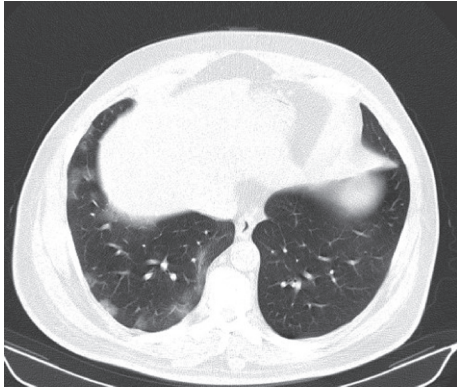


FIGURE 1: Spiral chest CT scan of the patient on day 12.

bilateral peripheral ground glass opacities with approximately 20% involvement of the lungs (Figure 1). He was admitted and received remdesivir (200 mg on the first day and continued with 100 mg daily from the 2nd to 5th day, afterwards). Oral prednisolone was changed to IV dexamethasone 4 mg BID. The treatment was continued for 5 days. The patient was discharged on the sixth day of admission without any antiviral agents or oral prednisolone tapering. On the discharge day, his facial palsy improved to the grade II/VI and he completely recovered from COVID-19 respiratory symptoms. After three months of follow-up, facial palsy improved completely. Written consent was obtained from the patient for reporting and publishing the results.

3. Discussion

This is a report of unilateral peripheral facial palsy in a COVID-19 patient with an excellent response to combination therapy of corticosteroids and remdesivir. Since the start of the pandemic, various antivirals have been administered off label with the succeeding articles justifying their use. A recent study by Beigel et al. has shown that remdesivir reduces the time to recovery in hospitalized COVID-19 patients [2]. Other studies have shown favipiravir to be effective as an oral agent in reducing viral clearance time [3, 4].

Bell's palsy has an annual incidence of 11.5–53.3 cases per 100,000 in a year in different populations [5]. However, there are increasing reports of Bell's palsy during the pandemic, either due to the viral infection or vaccination [6]. In a study by Codeluppi et al., there was an increased incidence of facial palsy during the COVID-19 pandemic and 21% of patients with Bell's palsy had a recent and active infection [7]. Prior evidence indicates that corticosteroids are effective in the treatment of Bell's palsy. However, there are debates on corticosteroid therapy during the COVID-19 pandemic, and it is reserved for serious cases. A recent consensus recommends treatment with short courses of corticosteroid therapy in grade V and VI Bell's palsy, in the absence of signs and symptoms suggestive of COVID-19 [8]. The concern about corticosteroid therapy is more in patients with COVID-19. Although corticosteroids are one

of the mainstays of treatment in severe and critical COVID-19, it is not recommended in patients with mild and moderate symptoms due to potential disease exacerbation [9, 10]. It seems that facial palsy associated with COVID-19 should be treated based on each patient's medical condition, as worse motor function based on House–Brackmann decreases the probability of complete recovery [11, 12]. Goh et al. reported a case of facial palsy 6 days after disease onset. The patient had an isolated lower motor neuron left facial palsy, and he was treated with oral prednisone and valacyclovir and lopinavir/ritonavir to reduce viral replication. However, he did not report a significant improvement after a week of treatment [13]. In another case report, a 57-year-old woman developed an acute left-side facial palsy, a week after developing symptoms of COVID-19. She only received symptomatic treatment and was reported to have a complete recovery after a month [14]. Figueiredo et al. reported a pregnant woman presented with an isolated facial palsy. She had a positive RT-PCR test for SARS-Cov-2 and was treated with corticosteroid, but the outcome was not reported [15]. In a case series by Lima et al., eight patients with COVID-19 and Bell's palsy were evaluated for clinical presentation and outcome [16]. Their patients had mild respiratory and systemic manifestations and grade II-III House–Brackmann, and none required hospitalization; seven patients received steroids from which four patients had complete recovery and three patients had partial recovery. However, concomitant use of antiviral agents is not reported.

There are reports of Bell's palsy following COVID-19 vaccination. Repajic et al. reported the first case of Bell's palsy following the 2nd dose of Pfizer-BioNTech COVID-19 vaccination in a 57-year-old Caucasian female. She was treated with prednisone and an antiviral agent, and her symptoms started to improve from the 14th day [17]. Their choice of antiviral treatment is not reported. Colella et al. also reported a patient developing Bell's palsy after the first dose of Pfizer-BioNTech COVID-19 vaccination [6]. He had a grade V House–Brackmann and received corticosteroids without improvement after 23 days of follow-up.

In our patient, soon after starting corticosteroid treatment, the course of COVID-19 progressed despite oral favipiravir therapy. In our experience, short-term corticosteroid therapy in combination with remdesivir may prove beneficial in patients with severe facial palsy associated with COVID-19. We suggest conduction of future clinical trials on concomitant administration of a potent antiviral agent and corticosteroid therapy in patients with severe Bell's palsy associated with COVID-19 to prevent potential disease exacerbation.

Data Availability

Data are available upon request from the authors.

Conflicts of Interest

The authors declare that they have no conflicts of interest.

References

- [1] J. W. House, "Facial nerve grading systems," *The Laryngoscope*, vol. 93, no. 8, pp. 1056–1069, 1983.
- [2] J. H. Beigel, K. M. Tomashek, L. E. Dodd et al., "Remdesivir for the treatment of covid-19 - final report," *New England Journal of Medicine*, vol. 383, no. 19, pp. 1813–1826, 2020.
- [3] Q. Cai, M. Yang, D. Liu et al., "Experimental treatment with favipiravir for COVID-19: an open-label control study," *Engineering*, vol. 6, no. 10, pp. 1192–1198, 2020.
- [4] A. A. Ivashchenko, K. A. Dmitriev, N. V. Vostokova et al., "AVIFAVIR for treatment of patients with moderate coronavirus disease 2019 (COVID-19): interim results of a phase II/III multicenter randomized clinical trial," *Clinical Infectious Diseases*, 2020.
- [5] W. Zhang, L. Xu, T. Luo, F. Wu, B. Zhao, and X. Li, "The etiology of Bell's palsy: a review," *Journal of Neurology*, vol. 267, no. 7, pp. 1896–1905, 2020.
- [6] G. Colella, M. Orlandi, and N. Cirillo, "Bell's palsy following COVID-19 vaccination," *Journal of Neurology*, vol. 21, 2021.
- [7] L. Codeluppi, F. Venturelli, J. Rossi et al., "Facial palsy during the COVID-19 pandemic," *Brain and Behavior*, vol. 11, no. 1, Article ID e01939, 2021.
- [8] P. Herman, C. Vincent, C. Parietti Winkler et al., "Consensus statement. Corticosteroid therapy in ENT in the context of the COVID-19 pandemic," *European Annals of Otorhinolaryngology, Head and Neck Diseases*, vol. 137, no. 4, pp. 315–317, 2020.
- [9] R. M. Johnson and J. M. Vinetz, "Dexamethasone in the Management of Covid-19," *British Medical Journal Publishing Group*, vol. 370, 2020.
- [10] Z. Yang, J. Liu, Y. Zhou, X. Zhao, Q. Zhao, and J. Liu, "The effect of corticosteroid treatment on patients with coronavirus infection: a systematic review and meta-analysis," *Journal of Infection*, vol. 81, no. 1, pp. e13–e20, 2020.
- [11] E. Urban, G. F. Volk, K. Geißler et al., "Prognostic factors for the outcome of Bells' palsy: a cohort register-based study," *Clinical Otolaryngology*, vol. 45, no. 5, pp. 754–761, 2020.
- [12] M. C. Yoo, Y. Soh, J. Chon et al., "Evaluation of factors associated with favorable outcomes in adults with Bell palsy," *JAMA Otolaryngology-Head and Neck Surgery*, vol. 146, no. 3, pp. 256–263, 2020.
- [13] Y. Goh, D. L. L. Beh, A. Makmur, J. Somani, and A. C. Y. Chan, "Pearls and Oysters: facial nerve palsy in COVID-19 infection," *Neurology*, vol. 95, no. 8, pp. 364–367, 2020.
- [14] C. Derollez, T. Alberto, I. Leroi, M.-A. Mackowiak, and Y. Chen, "Facial nerve palsy: an atypical clinical manifestation of COVID-19 infection in a family cluster," *European Journal of Neurology*, vol. 27, pp. 2670–2672, 2020.
- [15] R. Figueiredo, V. Falcão, M. J. Pinto, and C. Ramalho, "Peripheral facial paralysis as presenting symptom of COVID-19 in a pregnant woman," *BMJ Case Reports*, vol. 13, Article ID e237146, 2020.
- [16] M. A. Lima, M. T. T. Silva, C. N. Soares et al., "Peripheral facial nerve palsy associated with COVID-19," *Journal of Neuro-Virology*, vol. 26, no. 6, pp. 941–944, 2020.
- [17] M. Repajic, X. L. Lai, P. Xu, and A. Liu, "Bell's Palsy after second dose of Pfizer COVID-19 vaccination in a patient with history of recurrent Bell's palsy," *Brain, Behavior, and Immunity—Health*, vol. 13, Article ID 100217, 2021.