

## Case Report

# A Catheter-Related Bloodstream Infection by *Brevibacterium casei* in a Child with Acute Myeloid Leukemia: Case Report and Literature Review

Fumihiko Ochi <sup>1</sup>, Hisamichi Tauchi,<sup>1</sup> Kyoko Moritani,<sup>1</sup> Shinobu Murakami,<sup>2</sup> Hitoshi Miyamoto,<sup>2</sup> Mayo Ueda,<sup>1</sup> Koza Nagai,<sup>1</sup> Minenori Eguchi-Ishimae,<sup>1</sup> and Mariko Eguchi<sup>1</sup>

<sup>1</sup>Department of Pediatrics, Ehime University Graduate School of Medicine, Toon, Ehime 791-0295, Japan

<sup>2</sup>Clinical Laboratory Division, Ehime University Hospital, Toon, Ehime 791-0295, Japan

Correspondence should be addressed to Fumihiko Ochi; [fmochi2000@yahoo.co.jp](mailto:fmochi2000@yahoo.co.jp)

Received 21 October 2020; Revised 31 March 2021; Accepted 1 April 2021; Published 9 April 2021

Academic Editor: Ozgur Kasapcopur

Copyright © 2021 Fumihiko Ochi et al. This is an open access article distributed under the Creative Commons Attribution License, which permits unrestricted use, distribution, and reproduction in any medium, provided the original work is properly cited.

The most common organisms isolated from pediatric catheter-related bloodstream infections (CRBSIs) are Gram-positive cocci, such as coagulase-negative staphylococci and *Staphylococcus aureus*. There are few formal reports of *Brevibacterium casei* infection and even fewer reports of CRBSI due to this Gram-positive rod. Here we report the first case of CRBSI due to *B. casei* in an 8-year-old girl with acute myeloid leukemia in Japan. The isolate exhibited decreased susceptibility to  $\beta$ -lactam antibiotics. Antimicrobial therapy with meropenem and vancomycin, in addition to the removal of central venous catheter line, consequently led to a significant clinical improvement of the patient's symptoms. A literature review found available clinical courses in 16 cases (4 pediatric cases including our case) of *B. casei* infection. Our case and those in literature suggested that *B. casei* infection often occurs in patients with indwelling central venous catheters; the literature review further suggested that removal of central venous catheters is required in most cases. Special attention should be paid to the detection of opportunistic infections due to *Brevibacterium* spp. in immunocompromized children who are using a central venous catheter.

## 1. Introduction

There are only a few formal reports on *Brevibacterium casei* infections, especially in immunocompromized children. We report the first case of catheter-related bloodstream infection (CRBSI) due to *B. casei* in a child with acute myeloid leukemia (AML) in Japan.

Chemotherapy in the treatment of AML induces long-term neutropenia, which greatly increases the risk of infection. In addition, there is also a high risk of healthcare-associated infections, such as CRBSI, due to the need for long-term central venous catheterization.

*B. casei* is an obligately aerobic, catalase-positive, non-spore-forming, immotile, Gram-positive rod and a known human skin colonizer [1]. *B. casei* was not considered a human pathogen until the publication of a few reports of

infections in immunocompromized patients. Recently, *B. casei* has emerged as an opportunistic pathogen in immunocompromized hosts and has been associated with severe infections, such as bacteremia, brain abscess, pericardial infection, peritonitis, and endophthalmitis [2–15]. Previous studies have shown blood cultures to be the most common specimens from which *B. casei* was isolated. Reports of CRBSI due to *B. casei* in immunocompromized hosts are on the rise [16].

Currently, there are no large studies investigating appropriate antibiotics or treatment duration for *B. casei* infections. We therefore conducted a literature review to find an appropriate treatment. We summarized the previously reported cases of *B. casei* infection by performing a PubMed search from January 1995 to March 2020 (Table 1). Among the 16 patients with reported *B. casei* infections, 4 were

TABLE 1: Characteristics, treatment, and outcomes of the *Brevibacterium casei* infection cases identified in a PubMed search conducted in March 2020.

No	Age (y), sex	Underlying disease	Infection	Device	Empiric therapy (days <sup>‡</sup> )	Treatment after relapse (days <sup>‡</sup> )	Ref.
1	25, M	Choriocarcinoma	Sepsis	Permanent catheter	PIPC + TEIC (10)	PIPC + TOB (10)	[2]
2	46, F	NHL	CRBSI	CVC	CEX (10)	Device removal	[3]
3	N/A*	Neuroblastoma	CRBSI	Broviac catheter	N/A	N/A	[4]
4	18, F	AIDS	Sepsis, CRBSI	Port-a-cath	CPFX (14) + device removal	No relapse	[5]
5	34, M	AIDS	Sepsis, CRBSI	Hickman catheter	CAZ + VCM (8) + device removal	No relapse	[6]
6	43, F	Crohn's disease	CRBSI	Port-a-cath	VCM (15)	CVA/AMPC (3), MEPM (3), VCM (3) + device removal	[7]
7	31, M	N/A, HD	CRBSI	Hickman catheter	VCM (15)	VCM + antibiotic lock (15)	[7]
8	78, M	Cancer	Pericardial infection	N/A	VCM (11) + Pericardiocentesis	No relapse	[8]
9	62, F	PH	Sepsis, CRBSI	CVC	MFLX (21) + VCM (10) + device removal	No relapse	[9]
10	31, M	None	Brain abscess	N/A	Craniotomy/excision + CTX (7) + AMPC (28)	No relapse	[10]
11	37, M	CKH, PD	Peritonitis	PD catheter	CAZ + VCM (14)	Device removal	[11]
12	12, M	None	Endophthalmitis	N/A	CAZ <sup>†</sup> + VCM <sup>†</sup> + CEZ (5)	No relapse	[12]
13	33, F	SLE, PD	Peritonitis	PD catheter	CAZ + CEZ (14)	VCM (28) + device removal	[13]
14	6, M	ALL, FN	CRBSI	Hickman catheter	TAZ/PIPC + VCM (N/A)	No relapse	[14]
15	48, F	Breast cancer	CRBSI	Port-a-cath	CPFX (20)	TEIC (7) + device removal, LZD (7)	[15]
16	8, F	AML, FN	CRBSI	PICC	MEPM (19) + VCM (19) + device removal	No relapse	Our case

\*Child. †Intravitreal injection. ‡Duration of the treatment. AIDS, acquired immunodeficiency syndrome; ALL, acute lymphoblastic leukemia; AML, acute myeloid leukemia; AMPC, amoxicillin; CAZ, ceftazidime; CEZ, cefazolin; CEX, cephalixin; CKH, congenital kidney hypoplasia; CPFX, ciprofloxacin; CRBSI, catheter-related bloodstream infection; CTX, cefotaxime; CVA/AMPC, clavulanate/amoxicillin; CVC, central venous catheter; F, female; FN, febrile neutropenia; HD, hemodialysis; LZD, linezolid; M, male; MEPM, meropenem; MFLX, moxifloxacin; N/A, not available; NHL, non-Hodgkin's lymphoma; PD, peritoneal dialysis; PH, pulmonary hypertension; PIPC, piperacillin; Ref, reference; SLE, systemic lupus erythematosus; TAZ/PIPC, tazobactam/piperacillin; TEIC, teicoplanin; TOB, tobramycin; y, year; VCM, vancomycin.

pediatric patients (<15 years old), including our patient [2–15]. This report aims to present a case report of a CRBSI caused by a *B. casei* infection, review previous *B. casei* infections, and provide a concise review of the clinical background, risk factors, and management of infections due to this organism.

## 2. Case Report

An 8-year-old girl diagnosed with AML (standard risk) was transferred to our hospital. According to the AML12 protocol of the Japanese Pediatric Leukemia/Lymphoma Study Group (JPLSG), she received combination chemotherapy (cytarabine, methotrexate, mitoxantrone, idarubicin, and etoposide) as induction therapy and achieved complete remission. Neutropenia became apparent 6 days after maintenance therapy, with neutrophil counts of <500/ $\mu$ L, and the patient developed febrile episodes with shaking chills 9 days after maintenance therapy. She appeared toxic, and her temperature, blood pressure, pulse rate, and respiratory rate were 38.7°C, 88/48 mmHg, 108/min, and 24/min, respectively.

Laboratory examination revealed a decreased leukocyte count of <100/ $\mu$ L and elevated C-reactive protein level of 3.58 mg/dL (reference range, <0.5 mg/dL). After two consecutive blood cultures taken from the peripheral vein and peripherally inserted central catheter (PICC) line, meropenem (40 mg/kg/dose, 3 times/day) was administered as empiric therapy. The standard blood culture exhibited only coryneform Gram-positive, club-shaped, slightly curved rods from the aerobic bottle 1 day after culture. Her temperature, blood pressure, pulse rate, and respiratory rate were 36.7°C, 76/40 mmHg, 96/min, and 18/min, respectively. We then added vancomycin (15 mg/kg/dose, 4 times/day) to the treatment protocol and removed the PICC line on the second day of the febrile episode. The duration of PICC placement was 69 days.

Using a MALDI Biotyper (Bruker Daltonik GmbH, Bremen, Germany) with laser desorption ionization time-of-flight mass spectrometry, we identified *B. casei* in the positive blood cultures containing samples taken from the peripheral vein and PICC line [17]. *B. casei* also grew in the sample collected from the PICC tip, based on which we made a diagnosis of CRBSI caused due to *B. casei*.

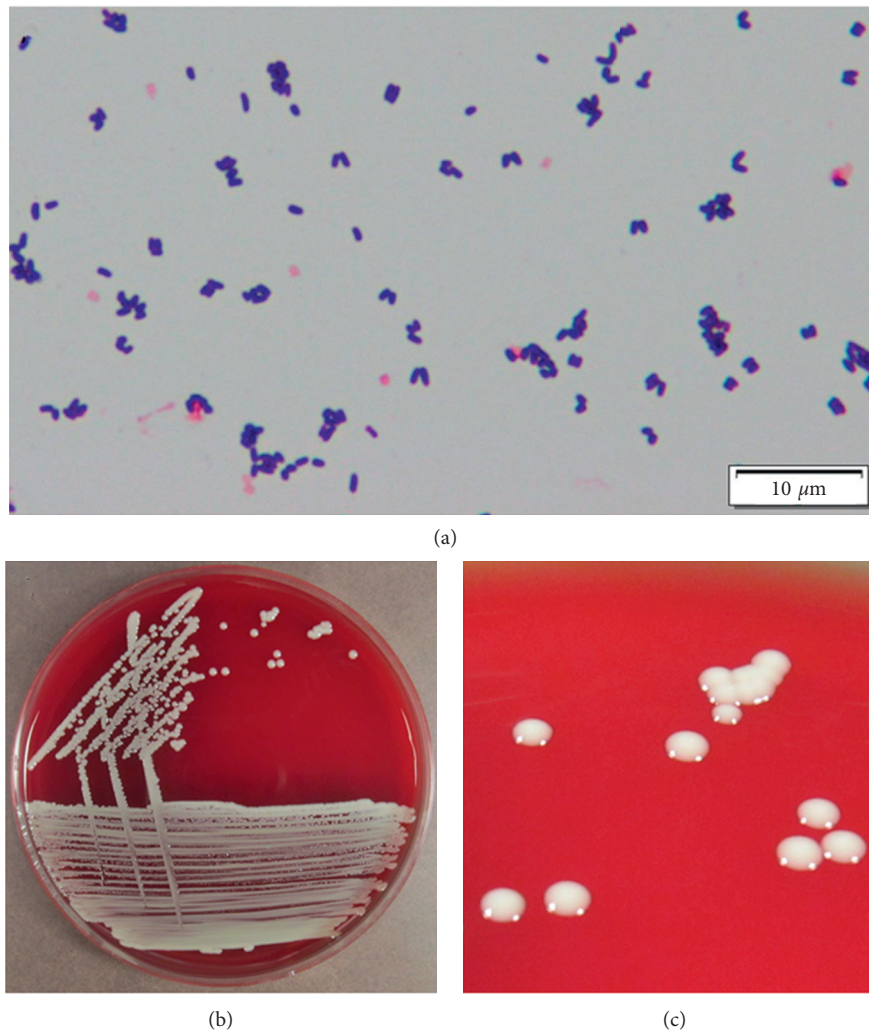


FIGURE 1: Macroscopic and microscopic appearance of *Brevibacterium casei*. (a) Gram-stained smears from blood samples cultured in bottles at 37°C for 24 h. (b) Macroscopic appearance of *B. casei* colonies after isolation from the patient and culture on a sheep blood agar plate incubated at 37°C for 24 h in a CO<sub>2</sub> atmosphere. (c) The colonies appeared gray-white in color, non-hemolytic, smooth, and round and had a distinctive cheese odor.

After a 24 h incubation at 37°C in a CO<sub>2</sub> atmosphere, the Gram-positive rods formed colonies on sheep blood agar that were whitish to gray-white in color, non-hemolytic, smooth, and round and had a distinctive cheese odor (Figure 1). The isolate was positive for catalase, α-glucosidase, and gelatin hydrolysis, while negative for urease, oxidase, and nitrate reduction. These biochemical features were typical of *B. casei*. Drug sensitivity tests were analyzed using the broth microdilution method. The minimum inhibitory concentration for the isolate was >4 μg/mL for ampicillin, sulbactam/ampicillin, and tazobactam/piperacillin; >2 μg/mL for cefazolin and cefmetazole; ≤2 μg/mL for cefepime; 0.25 μg/mL for meropenem; 2 μg/mL for clarithromycin; 4 μg/mL for ciprofloxacin; and 0.5 μg/mL for vancomycin.

There is no standardized treatment for *B. casei* bacteremia, and the Clinical and Laboratory Standards Institute 2011 criteria for interpreting susceptibility results are based on the recommendations that apply to *Corynebacterium* spp.

[18]. In our case, antimicrobial therapy with meropenem and vancomycin and PICC line removal consequently led to a significant clinical improvement of the symptoms. We performed antimicrobial treatment for 19 days until the patient's neutropenia was ameliorated, and she recovered without sequelae. After the chemotherapy as treatment of AML, the patient remained in remission. At present, she is undergoing close follow-up as an outpatient.

### 3. Discussion

The genus *Brevibacterium* consists of 45 species, of which only 10 have been isolated from clinical samples (*B. avium*, *B. casei*, *B. epidermidis*, *B. iodinum*, *B. linens*, *B. massiliense*, *B. mcbrellneri*, *B. otitidis*, *B. paucivorans*, and *B. sanguinis*). *B. casei* is the most frequently isolated *Brevibacterium* species from otherwise sterile human sites [19].

Most patients with *B. casei* infection presented with specific underlying conditions, such as malignant tumors,

renal failure, or an immunocompromized status (Table 1). Our patient presented with AML. Medical catheters are often required for treatment in patients with underlying diseases such as those mentioned. Patients with indwelling central venous catheters are at high risk of acquiring CRBSIs.

The most common organisms isolated from pediatric CRBSIs are coagulase-negative staphylococci and *Staphylococcus aureus*. Although *B. casei* is an extremely rare organism isolated from patients with CRBSI, it is crucial to be aware of the possibility of *B. casei* infection in immunocompromized hosts with catheter devices because central venous catheters and peritoneal dialysis catheters were the most common causes of *B. casei* infections (Table 1).

Interestingly, the *B. casei* isolates exhibited varying degrees of susceptibility to a variety of antimicrobial agents (Table 1). Although most isolates had  $\beta$ -lactam minimum inhibitory concentrations that fell within the susceptible range, some exhibited decreased susceptibility to all of the  $\beta$ -lactam antibiotics, such as in our case. Accordingly, the inclusion of glycopeptide administration in the definitive therapy is recommended. Almost all reported *B. casei* CRBSI cases were treated with glycopeptides.

In general, CRBSI management consists of systemic antibiotic therapy and catheter removal (if feasible). Catheter removal, in addition to systemic antimicrobial therapy administration, is recommended in circumstances such as sepsis, endocarditis, metastatic infection, thrombophlebitis, persistent bacteremia, subcutaneously tunneled central venous catheter infection, or port reservoir infection due to the high likelihood of severe and/or progressive infection with antibiotic therapy alone [20]. For children with CRBSI, some pediatricians favor attempting catheter salvage, such as antibiotic lock therapy, when feasible, given the greater difficulty of vascular access among children than among adults.

Five patients with CRBSI due to *B. casei* received antibiotic therapy without catheter removal (Nos. 2, 6, 7, 14, and 15), and four out of five patients with *B. casei* infection and no catheter removal had a relapsed infection. Conversely, in patients with CRBSI due to *B. casei* in whom catheter removal was performed as empiric therapy (0/4 patients), relapsed infections did not occur (Table 1). We performed both antibiotic administration and catheter removal in our case, and our patient recovered without sequelae. Thus, the removal of infected or unnecessary catheters, if possible, is desirable.

In conclusion, special attention should be paid to opportunistic infections due to *Brevibacterium* spp. in immunocompromized children who are using a central venous catheter. It is crucial to minimize the risk of infection from contaminated sources (needleless connectors, catheter hubs, or injection ports) and to remove infected or unnecessary catheters.

## Data Availability

No data were used to support this study.

## Consent

Written informed consent was obtained from the patient's parents for this publication.

## Conflicts of Interest

The authors declare that they have no conflicts of interest.

## Authors' Contributions

FO, HT, KM, KN, and MU managed the patient and prepared the manuscript. SM and HM performed the biochemical analysis and mass spectrometry. ME and ME-I reviewed the manuscript. All authors read and approved the final manuscript.

## Acknowledgments

The authors would like to thank Enago (<http://www.enago.jp>) for the English language review.

## References

- [1] G. Funke, A. von Graevenitz, J. E. Clarridge, and K. A. Bernard, "Clinical microbiology of coryneform bacteria," *Clinical Microbiology Reviews*, vol. 10, no. 1, pp. 125–159, 1997.
- [2] R. R. Reinert, N. Schnitzler, G. Haase et al., "Recurrent bacteremia due to *Brevibacterium casei* in an immunocompromised patient," *European Journal of Clinical Microbiology & Infectious Diseases*, vol. 14, no. 12, pp. 1082–1085, 1995.
- [3] S. S. E. Kaukoranta-Tolvanen, A. Sivonen, A. A. I. Kostiala, P. Hormila, and M. Vaara, "Bacteremia caused by *Brevibacterium* species in an immunocompromised patient," *European Journal of Clinical Microbiology & Infectious Diseases*, vol. 14, no. 9, pp. 801–804, 1995.
- [4] E. Castagnola, M. Conte, P. Venzano et al., "Broviac catheter-related bacteraemias due to unusual pathogens in children with cancer: case reports with literature review," *Journal of Infection*, vol. 34, no. 3, pp. 215–218, 1997.
- [5] P. Brazzola, R. Zbinden, C. Rudin, U. B. Schaad, and U. Heininger, "Brevibacterium casei sepsis in an 18-year-old female with AIDS," *Journal of Clinical Microbiology*, vol. 38, no. 9, pp. 3513–3514, 2000.
- [6] W. Janda, P. Tipirneni, and R. M. Novak, "Brevibacterium casei bacteremia and line sepsis in a patient with AIDS," *Journal of Infection*, vol. 46, no. 1, pp. 61–64, 2003.
- [7] I. Beukinga, H. Rodriguez-Villalobos, A. Deplano, F. Jacobs, and M. J. Struelens, "Management of long-term catheter-related *Brevibacterium* bacteraemia," *Clinical Microbiology and Infection*, vol. 10, no. 5, pp. 465–467, 2004.
- [8] J. P. Cannon, S. L. Spadoni, S. Pesh-Iman, and S. Johnson, "Pericardial infection caused by *Brevibacterium casei*," *Clinical Microbiology and Infection*, vol. 11, no. 2, pp. 164–165, 2005.
- [9] S. Ulrich, R. Zbinden, M. Pagano, M. Fischler, and R. Speich, "Central venous catheter infection with *Brevibacterium* sp. in an immunocompetent woman: case report and review of the literature," *Infection*, vol. 34, no. 2, pp. 103–106, 2006.
- [10] V. A. Kumar, D. Augustine, D. Panikar et al., "Brevibacterium casei as a cause of brain abscess in an immunocompetent

- patient," *Journal of Clinical Microbiology*, vol. 49, no. 12, pp. 4374–4376, 2011.
- [11] K. Poesen, G. Meeus, M. Boudewijns, J. Colaert, and P. Doubel, "Relapsing *Brevibacterium casei* Peritonitis: value of 16S rRNA gene sequencing in accurate species identification," *Peritoneal Dialysis International: Journal of the International Society for Peritoneal Dialysis*, vol. 32, no. 3, pp. 341–344, 2012.
- [12] A. Banu, S. Ks, and N. Er, "Post-traumatic endophthalmitis due to *Brevibacterium casei*: a case report," *Australasian Medical Journal*, vol. 6, no. 2, pp. 70–72, 2013.
- [13] M. M. Althaf, M. S. Abdelsalam, M. S. Alsunaid, and M. H. Hussein, "Brevibacterium casei isolated as a cause of relapsing peritonitis," *BMJ Case Report*, vol. 2014, Article ID bcr2014203611, 2014.
- [14] Z. S. Bal, S. Sen, D. Y. Karapinar, S. Aydemir, and F. Vardar, "The first reported catheter-related *Brevibacterium casei* bloodstream infection in a child with acute leukemia and review of the literature," *The Brazilian Journal of Infectious Diseases*, vol. 19, no. 2, pp. 213–215, 2015.
- [15] B. Magi, L. Migliorini, A. Sansoni, and M. G. Cusi, "Brevibacterium casei bacteraemia in a port-a-cath carrier patient: a case report," *Le Infezioni in Medicina*, vol. 26, no. 3, pp. 263–265, 2018.
- [16] E. Gruner, A. G. Steigerwalt, D. G. Hollis et al., "Human infections caused by *Brevibacterium casei*, formerly CDC groups B-1 and B-3," *Journal of Clinical Microbiology*, vol. 32, no. 6, pp. 1511–1518, 1994.
- [17] H. Miyamoto, T. Suzuki, S. Murakami et al., "Bacteriological characteristics of *Arcanobacterium haemolyticum* isolated from seven patients with skin and soft-tissue infections," *Journal of Medical Microbiology*, vol. 64, no. 4, pp. 369–374, 2015.
- [18] Clinical and Laboratory Standards Institute, *Methods for antimicrobial dilution and disk susceptibility testing of infrequently isolated and fastidious bacteria; approved guidelines M45-A2*, Clinical and Laboratory Standards Institute, Wayne, PA, 2011.
- [19] G. Wauters, G. Haase, V. Avesani et al., "Identification of a novel *Brevibacterium* species isolated from humans and description of *Brevibacterium sanguinis* sp. nov.," *Journal of Clinical Microbiology*, vol. 42, no. 6, pp. 2829–2832, 2004.
- [20] L. A. Mermel, M. Allon, E. Bouza et al., "Clinical practice guidelines for the diagnosis and management of intravascular catheter-related infection: 2009 Update by the Infectious Diseases Society of America," *Clinical Infectious Diseases*, vol. 49, no. 1, pp. 1–45, 2009.